

ALLEN Human Brain Atlas

TECHNICAL WHITE PAPER: CASE QUALIFICATION AND DONOR PROFILES

The case review process described here was employed for three components of the ALLEN **Human Brain Atlas**: (1) the Microarray Survey; (2) the Neurotransmitter Study; and (3) the Subcortex Study. Data for all other components of the Allen Human Brain Atlas were generated using banked tissue that underwent a separate screening process (see *In Situ Hybridization in the Allen Human Brain Atlas* white paper).

In general, postmortem tissue from males and females between 18 – 68 years of age and no known history of neuropsychiatric or neurological conditions ('control' cases) were eligible for inclusion in the Microarray Survey, Neurotransmitter Study, and Subcortex Study components of the Allen Human Brain Atlas. Key conditions for exclusion were:

- Brain injury or disease
- Epilepsy
- Drug/alcohol dependency
- > 1 hour on ventilator
- Positive for infectious disease
- Prion disease
- Chronic renal failure
- Cancer deaths
- Brain cancer
- Time since death > 30 hours

Brain tissue, cerebrospinal fluid and blood samples were collected after obtaining informed consent from decedent's next-of-kin. Institutional Review Board (IRB) review and approval was obtained for collection of tissue and non-identifying case information at the tissue banks and repositories that provided tissue for this project. Following tissue collection and freezing, additional tests and quality measures were performed to ensure the tissue and RNA met quality control (QC) criteria, and to rule out any previously undetected conditions incompatible with a 'control' diagnosis.

A Case Review Committee (CRC) of internal and external advisors reviewed all data and approved cases for inclusion in each study. The schematic in Figure 1 shows a timeline of formal CRC activities in relation to availability of screening data. A summary of screening tests and quality control measures and criteria is provided in Table 1. Specific donor profiles are provided in subsequent tables.

For additional detailed methodological information regarding these studies, please access the following technical white papers:

- *Microarray Survey in the Allen Human Brain Atlas*
- *In Situ Hybridization in the Allen Human Brain Atlas*

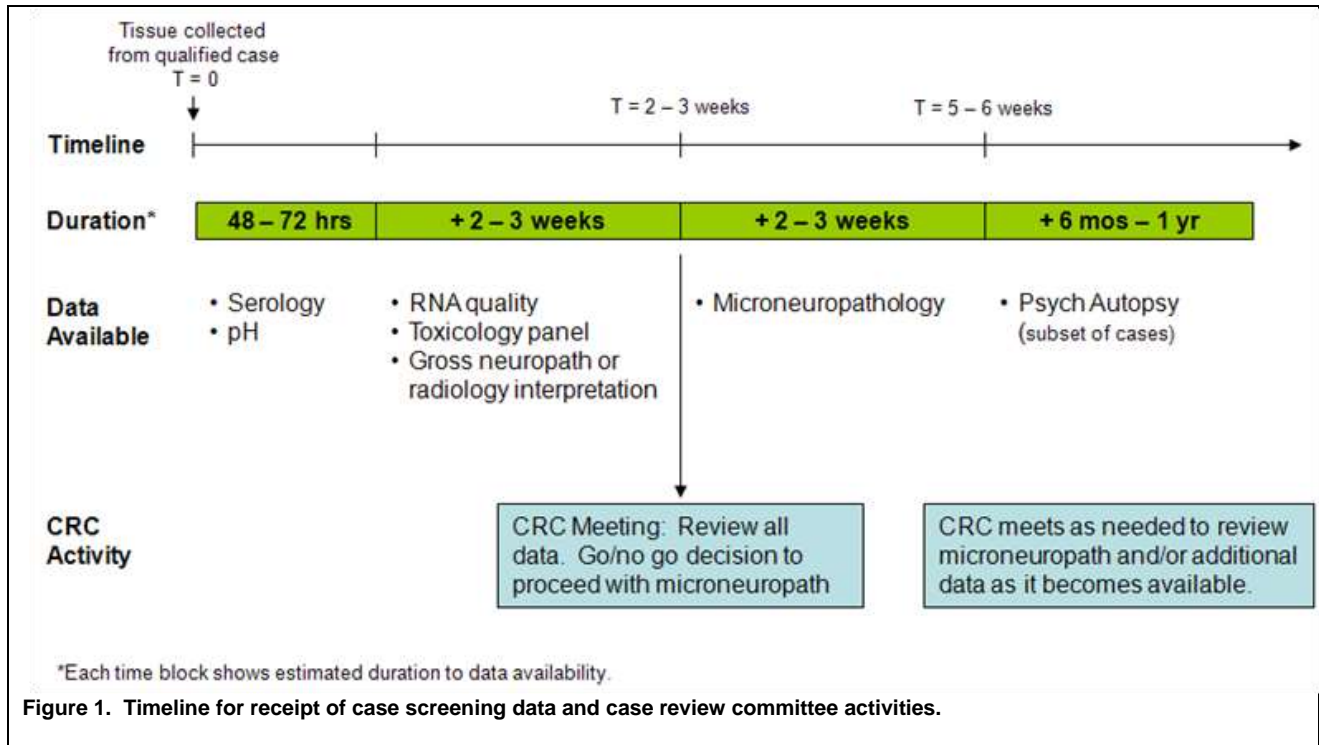


Table 1. Summary of case screens and quality control tests and criteria.

Test	Description	Passing Criteria
Serology	A safety precaution to evaluate blood serum for presence of antigens or antibodies for Hepatitis B, Hepatitis C or HIV1/HIV2.	Negative for all three tests.
pH	Measured in brain tissue homogenate and/or cerebrospinal fluid (CSF). Low pH levels are correlated with poor RNA quality.	pH ≥ 6.0
RNA quality	Assessed using Bioanalyzer-generated RNA Integrity Number (RIN) and Bioanalyzer electropherograms for 18s/28s ratios.	RIN ≥ 6.0, RNA amount ≥ 50ng, no obvious RNA degradation, no noticeable DNA or other contamination.
Toxicology	Postmortem blood is assessed for presence and concentration (when possible) of a broad range of therapeutic drugs and drugs with abuse potential.	Absence of drugs prescribed for neuropsychiatric disorders; absence of drugs at toxicologically significant levels (as reported by testing lab).
Gross neuropathology	Assessment of brain for gross morphological abnormalities indicating neuropathology (e.g. stroke, tumor, atrophy) by a radiologist using MRI data or by a pathologist using digital images of fresh brain sections.	‘Normal’ assessment by consulting radiologist or pathologist.
Microneuropathology	Analysis of histologically stained tissue sections to assess microscopic indications of pathology such as local ischemic events, abnormal levels of amyloid plaques or neurofibrillary tangles, or indications of abnormal cell morphology.	‘Normal’ assessment by consulting pathologist.

Table 2. Donor profile: H0351.1009.

Donor H0351.1009 – Microarray Survey, Neurotransmitter Study (ISH)			
Tissue Receipt Date	2/8/2011		
Sex	Male		
Age	57 years		
Race/Ethnicity	Caucasian		
Handedness	Cross-dominant		
Postmortem Interval	25.5 hours (estimated time of death to time that tissue is frozen)		
Serology	Pass		
Toxicology	Positive for caffeine and theobromine, at levels usually not toxicologically significant		
Tissue pH	6.9 (measured in frontal pole)		
RNA Quality	Pass	Region Tested	RIN value (Mean ± SD)
		Frontal poles	6.4 ± 0.4
		Occipital poles	6.1 ± 0.8
		Cerebellum (left & right)	7.1 ± 0.5
		Brainstem	5.6 ± 1.0
Neuropathology	Gross pathology: Normal Microneuropathology: Normal		
Tissue Received	12 left hemisphere 1 cm cerebral slabs in coronal orientation 7 right hemisphere cerebral slabs in coronal orientation 7 cerebellar slabs in sagittal orientation; 1 cm thickness 1 brainstem, whole		
Additional Medical Information	History of atherosclerotic cardiovascular disease		
Available Datasets	MRI, DTI, Photodocumentation		
	MRI	Viewable online, available for download	
	Blockface images	Left hemisphere	
	Histology		
	Nissl	Coronal left hemisphere, intact (6x8) and as mosaic reconstructions from 2x3 sections; individual 2x3 sections	
	SMI-32	2x3 sections	
	Gene Expression		
	Microarray	~400 samples from left cerebral cortex, striatum and white matter structures, including controls and sample replicates	
	ISH	88 and 176 genes in subcortex and cortex, respectively; right hemisphere	

Table 3. Donor profile: H0351.1010.

Donor H0351.1010 – Neurotransmitter Study (ISH)			
Tissue Receipt Date	2/23//2011		
Sex	Male		
Age	26 years		
Race/Ethnicity	Hispanic		
Handedness	Right		
Postmortem Interval	30 hours (estimated time of death to time that tissue is frozen)		
Serology	Pass		
Toxicology	Positive for atropine, caffeine, guaifenesin and theobromine, at levels usually not toxicologically significant		
Tissue pH	6.6 (measured in frontal pole)		
RNA Quality	Pass	Region Tested	RIN value (Mean ± SD)
		Frontal poles	6.4 ± 0.3
		Occipital poles	6.3 ± 0.6
		Cerebellum (left & right)	6.9 ± 0.4
		Brainstem	5.4 ± 0.0
Neuropathology	Gross pathology: Normal Microneuropathology: Normal, hemosiderosis noted		
Tissue Received	16 left hemisphere 1 cm cerebral slabs in coronal orientation 8 right hemisphere cerebral slabs in coronal orientation 7 cerebellar slabs in sagittal orientation; 1 cm thickness 1 brainstem, whole		
Additional Medical Information	No clinically remarkable history.		
Available Datasets	Histology		
	Nissl	Neurotransmitter Study histology (2x3)	
	SMI-32	Neurotransmitter Study histology (2x3)	
	Gene Expression		
	ISH	88 and 176 genes in subcortex and cortex, respectively; right hemisphere	

Table 4. Donor profile: H0351.1012.

Donor H0351.1012 – Microarray Survey, Neurotransmitter Study (ISH)			
Tissue Receipt Date	5/24/2011		
Sex	Male		
Age	31 years		
Race/Ethnicity	Caucasian		
Handedness	Right		
Postmortem Interval	17.5 hours (estimated time of death to time that tissue is frozen)		
Serology	Pass		
Toxicology	Positive for atropine, caffeine, ibuprofen and theobromine, at levels usually not toxicologically significant		
Tissue pH	6.8 (measured in frontal pole)		
RNA Quality	Pass	Region Tested	RIN value (Mean ± SD)
		Frontal poles	6.3 ± 0.3
		Occipital poles	5.8 ± 0.3
		Cerebellum (left & right)	6.9 ± 0.2
		Brainstem	6.4 ± 0.0
Neuropathology	Gross pathology: Normal Microneuropathology: Normal		
Tissue Received	18 left hemisphere 1 cm cerebral slabs in coronal orientation 8 right hemisphere cerebral slabs in coronal orientation 8 cerebellar slabs in sagittal orientation; 1 cm thickness 1 brainstem, whole		
Additional Medical Information	Sudden cardiac arrest. Benign spindle cell proliferation and dystrophic calcification in temporal horn of lateral ventricle, ~5 mm, possibly an old choroid plexus infarct or degenerated xanthogranuloma.		
Available Datasets	MRI, DTI, Photodocumentation		
	MRI	Viewable online, available for download	
	Blockface images	Left hemisphere	
	Histology		
	Nissl	Coronal left hemisphere, intact (6x8) and as mosaic reconstructions from 2x3 sections; individual 2x3 sections	
	SMI-32	2x3 sections	
	Gene Expression		
	Microarray	~500 samples from left cerebral, cerebellar and brainstem structures, including controls and sample replicates	
	ISH	88 and 176 genes in subcortex and cortex, respectively; right hemisphere	

Table 5. Donor profile: H0351.1015.

Donor H0351.1015 – Microarray Survey			
Tissue Receipt Date	10/11/2011		
Sex	Female		
Age	49 years		
Race/Ethnicity	Hispanic		
Handedness	Right		
Postmortem Interval	30 hours (estimated time of death to time that tissue is frozen)		
Serology	Pass		
Toxicology	Positive for caffeine, at levels usually not toxicologically significant		
Tissue pH	6.9 (measured in frontal pole)		
RNA Quality	Pass	Region Tested	RIN value (Mean ± SD)
		Frontal poles	7.0 ± 0.2
		Occipital poles	5.8 ± 1.2
		Cerebellum (left & right)	7.5 ± 0.2
		Brainstem	6.1 ± 0.4
Neuropathology	Gross Pathology: Normal Microneuropathology: Normal; modest numbers of hemosiderin laden macrophages noted in Virchow-Robin spaces in parietal and occipital lobes, mild arteriosclerosis		
Tissue Received	16 left hemisphere 1 cm cerebral slabs in coronal orientation 8 right hemisphere cerebral slabs in coronal orientation 8 cerebellar slabs in sagittal orientation; 1 cm thickness 1 brainstem, whole		
Additional Medical Information	Splenoectomy, hypothyroidism treated with Levothroid		
Available Datasets	MRI, DTI, Photodocumentation		
	MRI	Viewable online, available for download	
	Blockface images	Left hemisphere	
	Histology		
	Nissl	Coronal left hemisphere, intact (6x8) and as mosaic reconstructions from 2x3 sections; individual 2x3 sections	
	SMI-32	2x3 sections	
	Gene Expression		
	Microarray	~500 samples from left cerebral, cerebellar and brainstem structures including controls and sample replicates	

Table 6. Donor profile: H0351.1016.

Donor H0351.1016 – Microarray Survey, Neurotransmitter Study (ISH)			
Tissue Receipt Date	10/25/2011		
Sex	Male		
Age	55 years		
Race/Ethnicity	Caucasian		
Handedness	Right		
Postmortem Interval	18 hours (estimated time of death to time that tissue is frozen)		
Serology	Pass		
Toxicology	Positive for caffeine and theobromine, at levels usually not toxicologically significant		
Tissue pH	6.8 (measured in frontal pole)		
RNA Quality	Pass	Region Tested	RIN value (Mean ± SD)
		Frontal poles	6.4 ± 0.5
		Occipital poles	6.7 ± 0.7
		Cerebellum (left & right)	7.4 ± 0.3
		Brainstem	6.6 ± 0.2
Neuropathology	Gross Pathology: Normal Microneuropathology: Normal		
Tissue Received	16 left hemisphere cerebral slabs in coronal orientation 8 right hemisphere cerebral slabs in coronal orientation 9 cerebellar slabs in sagittal orientation; 1 cm thickness 1 brainstem, whole		
Additional Medical Information	Coronary artery atherosclerosis, prescriptions for clotting and high cholesterol.		
Available Datasets	MRI, DTI, Photodocumentation		
	MRI	Viewable online, available for download	
	Blockface images	Left hemisphere	
	Histology		
	Nissl	Coronal left hemisphere, intact (6x8) and as mosaic reconstructions from 2x3 sections; individual 2x3 sections	
	SMI-32	2x3 sections	
	Gene Expression		
	Microarray	~500 samples from left cerebral, cerebellar and brainstem structures, including controls and sample replicates	
	ISH	88 and 176 genes in subcortex and cortex, respectively; right hemisphere	

Table 7. Donor profile: H0351.2001.

Donor H0351.2001 – Microarray Survey			
Tissue Receipt Date	7/29/2009		
Sex	Male		
Age	24 years		
Race/Ethnicity	African American		
Handedness	Left		
Postmortem Interval	23 hours (estimated time of death to time that tissue is frozen)		
Serology	Pass		
Toxicology	Positive for atropine and caffeine, at levels usually not toxicologically significant		
Tissue pH	6.72		
RNA Quality	Pass	Region Tested	RIN value (Mean ± SD)
		Frontal poles	7.1 ± 0.4
		Occipital poles	6.5 ± 0.6
		Cerebellum (left & right)	8.1 ± 0.4
		Brainstem	7.1 ± 0.2
Neuropathology	MRI-based Radiology Report: Normal Microneuropathology: Normal		
Tissue Received	32 cerebral slabs in coronal orientation; 5 mm thickness 20 cerebellar slabs in sagittal orientation; 5 mm thickness 1 brainstem, whole		
Additional Medical Information	History of asthma		
Available Datasets	MRI, DTI, Photodocumentation		
	MRI	Viewable online, available for download	
	DTI	Viewable online, available for download	
	Histology		
	Nissl	Full coronal mosaic reconstructions from 2x3 sections; individual 2x3 sections	
	Gene Expression		
	Microarray	~1000 samples from > 300 left and right cerebral, cerebellar and brainstem structures, including controls and sample replicates	

Table 8. Donor profile: H0351.2002.

Donor H0351.2002 – Microarray Survey			
Tissue Receipt Date	8/25/2009		
Sex	Male		
Age	39 years		
Race/Ethnicity	African American		
Handedness	Left		
Postmortem Interval	10 hours (estimated time of death to time that tissue is frozen)		
Serology	Pass		
Toxicology	Positive for atropine, caffeine, lidocaine and monoethylglycinexylidide (MEGX) at levels usually not toxicologically significant		
Tissue pH	6.86		
RNA Quality	Pass	Region Tested	RIN value (Mean ± SD)
		Frontal pole (left & right)	7.5 ± 0.2
		Occipital pole (left & right)	7.1 ± 1.0
		Cerebellum (left & right)	8.6 ± 0.6
		Brainstem	7.3 ± 0.0
Neuropathology	MRI-based Radiology Report: Normal; possible small pituitary adenoma Microneuropathology: Normal; single neurofibrillary tangle in entorhinal cortex		
Tissue Received	25 cerebral slabs in coronal orientation; 5 mm thickness 17 cerebellar slabs in sagittal orientation; 5 mm thickness; 1 broken and irreparable 1 brainstem, whole		
Additional Medical Information	None known		
Available Datasets	MRI, DTI, Photodocumentation		
	MRI	Viewable online, available for download	
	DTI	Viewable online, available for download	
	Blockface images	Left and right hemispheres	
	Histology		
	Nissl	Full coronal 6x8 sections and full coronal mosaic reconstructions from 2x3 sections; individual 2x3 sections	
	SMI-32	2x3 sections	
	Gene Expression		
	Microarray	~1,000 samples from > 300 left and right cerebral, cerebellar and brainstem structures, including positive controls and sample replicates	

Table 9. Donor profile H0351.2003 .

Donor H0351.2003 – Subcortex Study			
Tissue Receipt Date	4/1/2010		
Sex	Female		
Age	48 years		
Race/Ethnicity	Caucasian		
Handedness	Right		
Postmortem Interval	24 hours (estimated time of death to time that tissue is frozen)		
Serology	Pass		
Toxicology	Positive for caffeine and theobromine at levels usually not toxicologically significant, acetone (1.6 mg/dL) consistent with low level fasting or diabetes.		
Tissue pH	6.65		
RNA Quality	Pass	Region Tested	RIN value (Mean ± SD)
		Frontal pole (left & right)	5.9 ± 0.7
		Occipital pole (left & right)	7.7 ± 0.4
		Cerebellum (left & right)	8.2 ± 0.3
		Brainstem	7.5 ± 0.1
Neuropathology	MRI-based Radiology Report: Normal; incidental 4mm angioma in left thalamus Microneuropathology: Normal; moderate arteriosclerosis and perivascular hemosiderosis.		
Tissue Received	6 cerebral slabs in coronal orientation, anatomy-based cuts 10 cerebellar slabs in sagittal orientation, average thickness: 7 mm		
Additional Medical Information	Enlarged heart, history of sleep apnea and morbid obesity		
Available Datasets	MRI, DTI, Photodocumentation		
	MRI	Available for download	
	DTI	Available for download	
	Histology		
	Nissl	2x3 sections	
	AchE	2x3 sections	
	Cytochrome Oxidase	2x3 sections	
	Gene Expression		
	ISH	Right hypothalamus/amygdala: 10 genes Left subcortical region extending from head of caudate nucleus posteriorly to the posterior aspect of the substantia nigra: 55 genes	

Table 9. Donor profile: H0372-006.

Donor H0372-006 – Subcortex Study			
Tissue Receipt Date	12/04/2009		
Sex	Male		
Age	44 years		
Race/Ethnicity	Caucasian		
Handedness	Right		
Postmortem Interval	24 hours (estimated time of death to time that tissue is frozen)		
Serology	Pass		
Toxicology	Positive for atropine, caffeine, lidocaine, theobromine, and dextro/levomethorphan; at levels usually not toxicologically significant		
Tissue pH	6.85		
RNA Quality	Pass	Region Tested	RIN value
		Frontal pole (left & right)	7.4
		Occipital pole (left & right)	6.3
		Cerebellum (left & right)	Not sampled
		Brainstem	6.0
Neuropathology	MRI-based Radiology Report: Normal Microneuropathology: Normal		
Tissue Received	4 cerebral slabs in coronal orientation Slab thickness: 3.25 - 3.5 mm		
Additional Medical Information	Flu-like symptoms prior to death		
Available Datasets	MRI, DTI, Photodocumentation		
	MRI	Available for download	
	DTI	Available for download	
	Histology		
	Nissl	2x3 sections	
	AchE	2x3 sections	
	Cytochrome Oxidase	2x3 sections	
	Gene Expression		
	ISH	Right hypothalamus/amygdala: 10 genes Left subcortical region extending from head of caudate nucleus posteriorly to the posterior aspect of the substantia nigra: 55 genes	